

A 12-week treatment with fractional CO₂ laser for vulvovaginal atrophy: a pilot study

S. Salvatore, R. E. Nappi*, N. Zerbinati[†], A. Calligaro[‡], S. Ferrero**, M. Origoni, M. Candiani and U. Leone Roberti Maggiore

Department of Obstetrics and Gynecology, Vita-Salute San Raffaele University and IRCCS San Raffaele Hospital, Milan; *IRCCS Policlinico S. Matteo Foundation and Department of Clinical, Surgical, Diagnostic and Pediatric Sciences, University of Pavia, Pavia; [†]University of Insubria, Varese; [‡]University of Pavia, Pavia; **Department of Obstetrics and Gynecology, San Martino Hospital and National Institute for Cancer Research, University of Genoa, Genoa, Italy

Key words: FRACTIONAL CO₂ LASER, MENOPAUSE, VAGINAL DRYNESS, DYSpareunia, VULVOVAGINAL ATROPHY

ABSTRACT

Objective This pilot study aimed to assess the efficacy and feasibility of fractional CO₂ laser in the treatment of vulvovaginal atrophy (VVA) in postmenopausal women.

Methods VVA symptoms were assessed before and after three applications of laser over 12 weeks in 50 women (age 59.6 ± 5.8 years) dissatisfied with previous local estrogen therapies. Subjective (visual analog scale) and objective (Vaginal Health Index Score, VHIS) measures were used during the study period to assess VVA. Quality of life was measured by using the SF-12. A subjective scale to evaluate the degree of pain related to the laser application and the degree of difficulty to perform the laser procedure was used.

Results Fractional CO₂ laser treatment was effective to improve VVA symptoms (vaginal dryness, vaginal burning, vaginal itching, dyspareunia, dysuria; $p < 0.001$) at 12-week follow-up, as well as the VHIS (13.1 ± 2.5 at baseline vs. 23.1 ± 1.9; $p < 0.001$). Both physical and mental scores of quality of life were significantly improved in comparison with baseline ($p < 0.001$). Satisfaction with the laser procedure was reported by 42 women (84%) and a minimal discomfort was experienced at the first laser application, mainly because of the insertion and the movements of the probe. Finally, the technique was very easy to perform in all women starting from the second application at week 4 and no adverse events were recorded during the study period.

Conclusions A 12-week treatment with the fractional CO₂ laser was feasible and induced a significant improvement of VVA symptoms by ameliorating vaginal health in postmenopausal women. Further controlled studies should be performed to confirm the present data and to assess the long-term effects of the laser procedure on vaginal tissues.

INTRODUCTION

Vulvovaginal atrophy (VVA) is an involution of the mucous membranes and tissues of the vulva and vagina caused by the drop of estrogen that occurs in women during menopause^{1–3}. In particular, the vagina becomes narrower and shorter and the introitus can constrict⁴. These modifications are commonly associated with the absence of sexual activity and/or with female sexual dysfunction^{5,6}. Other typical changes are represented by the progressive loss of elasticity and of rugal folds of the vaginal lining which becomes thin-

ner and may show petechiae. Sebaceous glands reduce the production of secretions and therefore, during sexual activity, lubrication is decreased and delayed^{4,5,7}. Patients with VVA complain of vaginal burning and discharges, itching, dryness, irritation, dysuria and dyspareunia^{8–11}. Moreover, the weakened tissues are more prone to develop traumas, tears, bleeding and infections^{4,7}. Recent reviews^{12,13} on the prevalence of VVA symptoms indicate that about 50% of postmenopausal women report at least one symptom associated with the condition. In spite of the relevance of VVA for quality of life, sexual function and relationships at

Correspondence: Dr U. Leone Roberti Maggiore, Department of Obstetrics and Gynaecology, IRCCS San Raffaele Hospital and Vita-Salute San Raffaele University, Via Olgettina 58-60, 20132 Milan, Italy; e-mail: ulrm@me.com

menopause^{14–16}, it remains a taboo subject in routine menopausal consultation, and health-care providers should be proactive in order to properly diagnose and adequately treat VVA symptoms^{12,13}.

Recent guidelines indicate that treatment options are diverse according to efficacy and safety, as well as severity of symptoms and women's preference^{17–19}. Lubricants are mainly used to relieve vaginal dryness during sexual activity and do not provide a long-term solution, whereas consistent use of moisturizers may have a long-lasting effect, especially if women maintain regular sexual activity. A novel selective estrogen receptor modulator, ospemifene, has been developed for the treatment of dyspareunia in postmenopausal women with VVA, and it has been demonstrated to be an effective and safe treatment both at 12 weeks and 12 months^{20,21}. Nowadays, hormonal replacement therapy (HRT) and local estrogens are the most common prescriptions to treat VVA. HRT should be considered for climacteric symptoms in the absence of contraindications, whereas local estrogens are primarily indicated to both alleviate symptoms and reverse atrophic anatomical changes in the cases where VVA represents the sole menopausal complaint^{17–19}. Although local estrogen therapies are effective and safe at very low doses^{1,3,5}, the rate of medication adherence is quite variable (52–74%)²², mainly due to safety concerns, inconvenience, and inadequate symptom relief from available treatments^{23,24}. In addition, data on the long-term safety (more than 1 year) of local estrogen treatments are lacking and, even though they do not seem to increase the risk of venous thromboembolism²⁵, no data are available in high-risk patients^{17–19}. Furthermore, women with breast cancer and other estrogen-dependent gynecological malignancies, who are at very high risk of VVA and associated sexual symptoms²⁶, require special consideration and an individualized counseling before prescribing any kind of local estrogen therapy²⁷.

That being so, there are many postmenopausal women who, for one reason or another, remain untreated, and any forthcoming potential option is welcome to overcome barriers, poor efficacy and contraindications to effectively handle VVA symptoms. Vaginal moisturizers may be effective in relieving VVA symptoms by exerting some eutrophic effect²⁸ and it is, then, conceivable that a procedure inducing the production of new collagen and elastic fibers may be used to potentially treat VVA²⁹. Fractional CO₂ laser has shown safety and remodelling tissue properties in many body regions, such as the skin of the face, neck and chest^{30–33}. In a recent *ex vivo* study on vaginal specimens collected during reconstructive pelvic surgery and treated with fractional CO₂ laser at pre-determined parameters, fractional CO₂ laser has shown connective tissue remodelling without damage or side-effects³⁴.

On the basis of these preliminary experiences, the present pilot study was designed to assess the efficacy and feasibility of fractional CO₂ laser in the treatment of VVA in postmenopausal women.

METHODS

Study design

This prospective pilot study was conducted between January and December 2013 and included postmenopausal women with symptoms related to VVA. The study protocol was approved by the Hospital Research Review Committee. Women entered the study after an informed written consent was obtained.

Study population

Out of 54 patients selected to participate to this pilot study, 50 postmenopausal women (92.6%) were recruited. Inclusion criteria for referral were: symptoms of VVA (vaginal dryness and/or dyspareunia rated as moderate/severe most bothersome symptoms³⁵); age > 50 years; absence of menstruation for ≥ 12 months; not responding/being unsatisfied with previous local estrogen therapies. Exclusion criteria were: use of any hormone replacement therapies (either systemic or local) within the 6 months prior to inclusion in the study; use of vaginal moisturizers, lubricants or any other local preparation within the 30 days prior to inclusion in the study; acute or recurrent urinary tract infections; active genital infections (e.g. herpes genitalis, candida); prolapse staged ≥ II according to the pelvic organ prolapse quantification system³⁶; previous reconstructive pelvic surgery; any serious disease or chronic condition that could interfere with study compliance; psychiatric disorders precluding informed consent.

Study protocol

Postmenopausal women were treated intravaginally with the fractional microablative CO₂ laser system (SmartXide² V²LR, Monalisa Touch, DEKA, Florence, Italy), using the following setting: dot power 30 watt, dwell time 1000 μs, dot spacing 1000 μm and the smart stack parameter from 1 to 3. Such pre-determined parameters were selected on the basis of *ex vivo* data obtained from vaginal wall specimens (Figure 1) demonstrating connective tissue remodelling, without showing any kind of damage to the surrounding tissues³². After decreasing the dot power to 20 watt, the vaginal introitus was initially treated and laser energy was transmitted through a vaginal probe (Figure 2) which was then slowly inserted and rotated along the vaginal canal, in order to provide a complete treatment of the vaginal wall. The laser was projected towards a 45° oriented mirror placed at the tip of the probe so that it was only reflected on the vaginal walls but not on the uterine cervix. A treatment cycle included three laser applications. Time points of the study were at baseline (T1), at week 4 (T2), at week 8 (T3), and at week 12 (T4), after 4 weeks from the last laser application. The procedure was performed in the outpatient clinic and did not require any specific preparation (e.g. analgesia/anesthesia). Patients were recommended to avoid coital

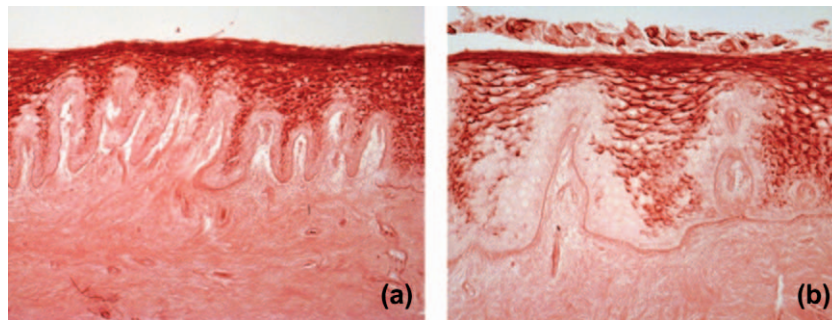


Figure 1 Postmenopausal vaginal mucosa (a) before and (b) 1 month after fractional CO₂ laser treatment. In (b) note the much thicker epithelium and the wide columns of large epithelial cells rich in glycogen (red). Compare the most superficial layers of the epithelium before and after treatment: small and closely compacted cells (a) and large detaching cells rich in glycogen (b). A much better organized connective tissue both in the lamina propria and in the core of the papillae (b) was also visible. Original magnification 200 ×; periodic acid Schiff reagent reaction

sexual activity for at least 3 days from each laser application because a mild inflammatory reaction may last up to 48 h.

Data collection

Sociodemographic characteristics of the study sample were collected at baseline (T1) and inclusion/exclusion criteria were verified before starting the first laser application. At each time point of the study (T2, T3, T4), women were evaluated by using the Vaginal Health Score Index (VHS) which consists of five measures: elasticity, fluid volume, pH, epithelial integrity and moisture. Each parameter is graded from 1 to 5. If the total score is <15, the vagina is considered atrophic³⁷. The intensity of VVA symptoms (vaginal burning, vaginal itching, vaginal dryness, dyspareunia and dysuria) was measured using a 10-cm visual analog scale (VAS), where the left extreme of the scale indicated ‘absence of symptom’ and the right indicated ‘symptom as bad as it could be’. The intensity of VVA symptoms was evaluated before starting the first laser application (T1) and at T2, T3, and T4. At T1 and at T4, postmenopausal women completed the Italian version of the Short Form 12 (SF-12) to assess physical (PCS12) and mental (MCS12) component summary scores of quality of life³⁸.

After each laser application, the physician evaluated the degree of difficulty encountered in the procedure using a five-point Likert scale (very easy, easy, neutral, difficult, very

difficult). At the same time, each patient recorded the degree of pain caused by the insertion of the probe, the movements of the probe and the application of laser by using a 10-cm VAS, where the left extreme of the scale indicated ‘absence of pain’ and the right indicated ‘pain as bad as it could be’.

At 12-week follow-up (T4), the women rated the overall degree of satisfaction with the treatment by answering the following question: ‘Taking into consideration the variations in VVA symptoms, in overall well-being and quality of life, as well as the adverse effects experienced, if any, how would you define the level of satisfaction with the laser treatment?’. Answers were scored on a five-point Likert scale (very satisfied, satisfied, uncertain, dissatisfied, very dissatisfied). Satisfaction with the treatment was defined when the answers were ‘very satisfied’ or ‘satisfied’. According to the intention-to-treat analysis, those women unable to tolerate the insertion of the probe due to the degree of VVA and/or vaginal stenosis were considered as ‘very dissatisfied’.

Statistical analysis

Data presented in the text and tables were reported as mean ± standard deviation, as median and as percentage (%). Continuous variables were analyzed by using the paired *t*-test and the signed rank test accordingly to data distribution. Data were analyzed using the Sigma Stat software version 3.5 and the SPSS software version 13.0 (SPSS Science, Chicago, IL, USA).

RESULTS

The main characteristics of this study population are described in Table 1. Forty-nine patients (98.0%) who enrolled in the study completed the treatment with fractional CO₂ laser and returned at 12-week follow-up. One patient (2.0%) could not be treated because her vagina was too narrow and not compliant with the vaginal probe.




Figure 2 The vaginal probe used to perform the fractional CO₂ laser procedure

Table 1 Baseline characteristics of the study population. Data are given as mean ± standard deviation, *n* (%) or median (range)

Age (years)	59.6 ± 5.8
Body mass index (kg/m ²)	23.8 ± 1.6
Smokers	19 (38.0%)
Level of education	
primary	3 (6.0%)
secondary	30 (60.0%)
university	17 (34.0%)
Patients with previous live births	45 (90.0%)
Parity	1 (1–3)
Sexual active women	45 (90.0%)
Previous systemic HRT	16 (32.0%)
Duration of previous HRT (months)	18 (2–26)

HRT, hormone replacement therapy

Changes in VHIS, VVA symptoms and SF-12

Table 2 reports the mean (± standard deviation) score of the VHIS at baseline (13.1 ± 2.5) and during the study period. After the first laser application (T2), the VHIS improved significantly (*p* < 0.001) with a further improvement after the second (*p* < 0.001) (T3) and the third laser application (*p* < 0.001) (T4). At T1, VVA symptoms were reported: vaginal dryness by 43 women (86.0%), vaginal burning by 45 (90.0%), vaginal itching by 40 (80.0%), and dysuria by 37 (74.0%). Dyspareunia was experienced by all (100.0%) women who were sexually active. Table 2 reports that each VVA symptom significantly improved at 12-week follow-up (*p* < 0.001) (T4) as compared with T1.

As far as quality of life as measured by SF-12 was concerned, the PCS12 significantly improved at T4 in comparison with T1 (50.0 ± 5.9 vs. 44.6 ± 11.0; *p* < 0.001). The same significant improvement was observed for the MCS12 (42.6 ± 10.6 at T1 vs. 47.0 ± 6.9 at T4; *p* < 0.001).

Table 2 Vaginal Health Index Score (VHIS) and intensity of vulvovaginal symptoms during the study period with the fractional microablative CO₂ laser system. Data are given as mean ± standard deviation (*n*)

	Baseline (T1) (first laser)	4-week follow-up (T2) (second laser)	8-week follow-up (T3) (third laser)	12-week follow-up (T4)
VHIS	13.1 ± 2.5	17.1 ± 1.9 [†]	22.1 ± 1.9 ^{†‡}	23.1 ± 1.9 ^{†‡}
Vaginal dryness (cm) [*]	8.3 ± 2.1 (43)	5.5 ± 2.9 [†] (42)	3.4 ± 2.5 ^{†‡} (42)	2.7 ± 1.9 ^{†‡} (42)
Vaginal burning (cm) [*]	6.4 ± 2.7 (45)	4.7 ± 2.2 (44)	3.8 ± 2.5 (44)	2.9 ± 2.4 (44)
Vaginal itching (cm) [*]	6.1 ± 3.0 (40)	3.3 ± 3.1 [†] (39)	2.1 ± 2.8 ^{†‡} (39)	1.5 ± 1.7 ^{†‡} (39)
Dyspareunia (cm) [*]	8.1 ± 2.8 (45)	5.7 ± 3.2 [†] (44)	4.5 ± 3.0 ^{†‡} (44)	3.3 ± 2.3 ^{†‡} (44)
Dysuria (cm) [*]	5.0 ± 2.4 (37)	2.8 ± 1.3 [†] (36)	2.0 ± 0.9 ^{†‡} (36)	1.1 ± 1.1 ^{†‡,***} (36)

^{*}, Measured on a 10-cm VAS scale (range 0–10); [†], statistical significant difference with T1; [‡], statistical significant difference with T2;

^{***} statistical significant difference with T3

Women’s satisfaction with the laser procedure

At T4, 16 (32.0%) women were very satisfied, 26 (52.0%) were satisfied, seven (14.0%) were uncertain and one (2.0%) was very dissatisfied with the fractional CO₂ laser procedure.

Characteristics of the laser procedure

The time required for the first laser application at T1 was 5.0 ± 1.2 min with a significant reduction in the time required for the execution of the procedure at T2 (4.1 ± 0.9 min; *p* < 0.001) and T3 (3.8 ± 0.6 min; *p* < 0.001) in comparison with baseline (T1).

Table 3 reports the intensity of pain perceived by the women during the laser procedure (insertion of the probe, movements of the probe and application) and the evaluation of the degree of difficulty encountered by the physician with this technique, demonstrating a significant reduction of pain during the study period and that the technique was very easy to perform in all women starting from the second application (T2). No adverse events (i.e. infections, worsening of symptoms) related to the fractional CO₂ laser procedure were recorded throughout the study period.

DISCUSSION

The present pilot study demonstrated for the first time that fractional microablative CO₂ laser is effective and easy to perform for the treatment of VVA in postmenopausal women. Indeed, the results of the current study showed that a treatment cycle of three laser applications significantly improved both most bothersome symptoms of VVA and scores of vaginal health at 12-week follow-up in women not responding/being unsatisfied with previous local estrogen therapies. A

Table 3 Pain related to fractional microablative CO₂ laser application and degree of difficulty to perform the procedure. Data are given as mean \pm standard deviation or *n* (%).

	Baseline (T1) (first laser)	4-week follow-up (T2) (second laser)	8-week follow-up (T3) (third laser)
<i>Pain experienced</i>			
During insertion of probe (cm)	4.7 \pm 1.6	2.6 \pm 1.5*	0.4 \pm 0.5*,†
Due to movements of probe (cm)	2.6 \pm 1.5	1.0 \pm 0.8*	0.2 \pm 0.4*,†
During laser application (cm)	0.6 \pm 0.8	0.3 \pm 0.5*	0.1 \pm 0.4*
<i>Degree of difficulty encountered in laser procedure</i>			
Very easy	41 (82.0%)	49 (100%)	49 (100%)
Easy	8 (16.0%)	0 (0%)	0 (0%)
Neutral	0 (0%)	0 (0%)	0 (0%)
Difficult	0 (0%)	0 (0%)	0 (0%)
Very difficult	1 (2.0%)	0 (0%)	0 (0%)

* , Statistical significant difference with T1; †, statistical significant difference with T2

positive effect on VVA symptoms was already evident after the first laser application and further increased at the end of the study period, in which even a significant improvement of both physical and mental scores of quality of life was observed in comparison with baseline. In addition, at the second laser application, the physician judged the performance ‘very easy’ in all cases, whereas women reported only minimal discomfort at the first laser application, mainly related to the insertion and the movements of the probe. At 12-week follow-up, the large majority of women (84.0%) were satisfied with the treatment and no related adverse events were recorded, but further long-term data on a larger sample of postmenopausal women are necessary to drive conclusions on laser technology being safe and effective in the treatment of VVA.

The anti-aging and regenerative medicine approach is an emerging reality in every field of human health. The feminization of aging is a real challenge world-wide³⁹ and the loss of estrogen, as a consequence of menopause, seems to be a turning point for a variety of conditions, including skin and urogenital aging^{40,41}. However, recent trends in menopausal treatments^{17–19,42} include many non-hormonal strategies to promote active aging and, after the publication of the Women’s Health Initiative studies, attitudes to the management of urogynecological and sexual health have significantly changed⁴³. For instance, the age-standardized rate of initiation of hormones (no more than 1 year after menopause onset) in newly postmenopausal women decreased by 69.9% in France⁴⁴. Moreover, systemic hormone treatments alleviate VVA symptoms in the majority of women, but they should be prescribed for climacteric syndrome and are best around the time of menopause, whereas local hormone treatments are indicated when VVA is the sole consequence of estrogen deprivation^{17–19,42}. However, vaginal non-hormonal treatments²⁸ are an integral part of an overall strategy to promote successful urogenital aging, especially in those women avoiding local estrogens for several reasons, i.e. fears, side-effects, convenience, poor compliance, lack of efficacy, contraindications^{17,23,24}. In spite of the lack of long-term, well-controlled data, many substances alone and/or in combination are used to treat VVA symptoms locally,

including hyaluronic acid, vitamin E and phytoestrogens^{17–19,28}, in order to counteract the loss of mucosal elasticity and hydration^{1,3,10}. Indeed, VVA has a negative impact on sex and relationships, affecting also self-esteem and quality of life¹³ and women are in need of multiple options according to personal beliefs, past experiences, preferences and satisfaction²⁴. Special care should be devoted to help women receiving endocrine therapy for breast cancer and reporting common and often severe urogenital side-effects⁴⁵, with a significant impairment of sexual function and quality of life, especially at younger age⁴⁶. That notwithstanding, the development of new non-hormonal strategies, such as laser technology, for the successful and safe treatment of VVA symptoms deserves attention and further investigation. Evaluation of change in individual symptoms such as vaginal dryness and/or dyspareunia is an important, unbiased primary analysis of efficacy in VVA studies³⁵. Our preliminary data showed that the laser application is easy to perform and is well tolerated by women who subjectively perceived a clinical benefit that was confirmed by the progressive improvement of the vaginal environment, as measured by the VHIS recorded by the physician. The mechanisms leading to this sort of ‘rejuvenation’ of the vaginal walls remain to be elucidated, as well as the duration of the changes induced by the laser application. It is conceivable that the effect on collagen remodelling that we have preliminarily demonstrated in *ex vivo* vaginal specimens³⁵ is quite similar to what it can be observed *in vivo* at the skin level⁴⁷, resulting in a considerable reduction of wrinkles depending on the area of the face⁴⁸. Interestingly enough, such collagen remodeling in the skin was still present after 3 months from the last laser session and confirms the long-term effect of the treatment⁴⁷.

However, this pilot study has several limitations: small sample size, short duration of the study, lack of long-term follow-up, and absence of a comparator (placebo or other active treatment). On the other hand, we designed the study mainly to demonstrate the feasibility and efficacy of the laser procedure on vaginal tissues in the clinical practice of menopause, and, in particular, to prove the activity of fractional CO₂ laser in those women being previously treated with

hormones, without significant clinical benefits. We believe this is a strength of this study to guide further research both in populations of women with contraindications to hormonal treatments and, therefore more difficult to manage, i.e. women with breast cancer, and in women who may be willing to associate hormonal and non-hormonal treatments with laser technology for a possible better outcome on VVA symptoms. Indeed, it is likely that a synergistic effect could be demonstrated with multiple treatment options, in combination or sequentially, and this may be relevant for elderly women suffering from the long-term consequence of estrogen deprivation, especially vaginal stenosis and other urogenital conditions⁴⁹. However, when laser therapy is combined or followed by local estrogen therapy, we cannot exclude a stronger absorption even of very low-dose products, due to the improvement of the atrophic condition. Given the importance of this effect for safety issues, several study designs are needed to address risks and benefits of laser treatment according to women's personal history.

In conclusion, this pilot study demonstrated that the treatment with the microablative CO₂ laser of postmenopausal with VVA symptoms is feasible, efficacious and safe in the short term at 12-week follow-up. If these findings are confirmed by larger, long-term, well-controlled studies, there will be an additional safe and effective option to treat VVA symptoms and to counteract urogenital aging in menopausal practice.

Conflict of interest During the past 2 years, Dr Nappi had financial relationships (lecturer, member of advisory boards and/or consultant) with Bayer-Schering Pharma, Eli Lilly, Gedeon-Richter, HRA Pharma, Merck Sharpe & Dohme, Novo Nordisk, Pfizer Inc, Shionogi Limited, Teva/Theramex. Dr Salvatore had financial relationships (lectures, member of advisory boards and/or consultant) with Pfizer Inc and Astellas. The other authors did not report any potential conflicts of interest.

Source of funding Nil.

References

- Castelo-Branco C, Cancelo MJ, Villero J, Nohales F, Juliá MD. Management of post-menopausal vaginal atrophy and atrophic vaginitis. *Maturitas* 2005;52:S46–52
- Calleja-Agius J, Brincat MP. Urogenital atrophy. *Climacteric* 2009;12:279–85
- Archer DF. Efficacy and tolerability of local estrogen therapy for urogenital atrophy. *Menopause* 2010;17:194–203
- Mehta A, Bachmann G. Vulvovaginal complaints. *Clin Obstet Gynecol* 2008;51:549–55
- Simon JA. Identifying and treating sexual dysfunction in postmenopausal women: the role of estrogen. *J Womens Health (Larchmt)* 2011;20:1453–65
- Levine KB, Williams RE, Hartmann KE. Vulvovaginal atrophy is strongly associated with female sexual dysfunction among sexually active postmenopausal women. *Menopause* 2008;5:661–6
- Goldstein I. Recognizing and treating urogenital atrophy in postmenopausal women. *J Womens Health (Larchmt)* 2010;19:425–32
- Santoro N, Komi J. Prevalence and impact of vaginal symptoms among postmenopausal women. *J Sex Med* 2009;6:2133–42
- Pastore LM, Carter RA, Hulka BS, Wells E. Self-reported urogenital symptoms in postmenopausal women: Women's Health Initiative. *Maturitas* 2004;49:292–303
- Palacios S. Managing urogenital atrophy. *Maturitas* 2009;63:315–18
- Nappi RE, Lachowsky M. Menopause and sexuality: prevalence of symptoms and impact on quality of life. *Maturitas* 2009;63:138–41
- Parish SJ, Nappi RE, Krychman ML, et al. Impact of vulvovaginal health on postmenopausal women: a review of surveys on symptoms of vulvovaginal atrophy. *Int J Womens Health* 2013;5:437–47
- Nappi RE, Palacios S. Impact of vulvovaginal atrophy on sexual health and quality of life at postmenopause. *Climacteric* 2014;17:3–9
- Nappi RE, Kokot-Kierepa M. Women's voices in the menopause: results from an international survey on vaginal atrophy. *Maturitas* 2010;67:233–8
- Nappi RE, Kokot-Kierepa M. Vaginal Health: Insights, Views and Attitudes (VIVA) – results from an international survey. *Climacteric* 2012;15:36–44
- Nappi RE, Kingsberg S, Maamari R, Simon J. The CLOSER (Clarifying Vaginal Atrophy's Impact On Sex and Relationships) Survey: Implications of vaginal discomfort in postmenopausal women and in male partners. *J Sex Med* 2013;10:2232–41
- Sturdee DW, Panay N; International Menopause Society Writing Group. Recommendations for the management of postmenopausal vaginal atrophy. *Climacteric* 2010;13:509–22
- Rees M, Pérez-López FR, Ceasu I, et al. EMAS clinical guide: low-dose vaginal estrogens for postmenopausal vaginal atrophy. *Maturitas* 2012;73:171–4
- NAMS. Management of symptomatic vulvovaginal atrophy: 2013 position statement of the North American Menopause Society. *Menopause* 2013;20:888–902
- Portman DJ, Bachmann GA, Simon JA; Ospemifene Study Group. Ospemifene, a novel selective estrogen receptor modulator for treating dyspareunia associated with postmenopausal vulvar and vaginal atrophy. *Menopause* 2013;20:623–30
- Goldstein SR, Bachmann GA, Koninckx PR, Lin VH, Portman DJ, Ylikorkala O; the Ospemifene Study Group. Ospemifene 12-month safety and efficacy in postmenopausal women with vulvar and vaginal atrophy. *Climacteric* 2014;17:173–82
- Shulman LP, Portman DJ, Lee WC, et al. A retrospective managed care claims data analysis of medication adherence to vaginal estrogen therapy: implications for clinical practice. *J Womens Health (Larchmt)* 2008;17:569–78
- Kingsberg SA, Wysocki S, Magnus L, Krychman ML. Vulvar and vaginal atrophy in postmenopausal women: findings from the REVIVE (REal Women's Views of Treatment Options for

- Menopausal Vaginal ChangEs) survey. *J Sex Med* 2013;10:1790–9
24. Kingsberg SA, Krychman ML. Resistance and barriers to local estrogen therapy in women with atrophic vaginitis. *J Sex Med* 2013;10:1567–74
 25. Suckling J, Lethaby A, Kennedy R. Local oestrogen for vaginal atrophy in postmenopausal women. *Cochrane Database Syst Rev* 2006 Oct 18;(4):CD001500
 26. Sadovsky R, Basson R, Krychman M, et al. Cancer and sexual problems. *J Sex Med* 2010;7:349–73
 27. Pruthi S, Simon JA, Early AP. Current overview of the management of urogenital atrophy in women with breast cancer. *Breast J* 2011;17:403–8
 28. Sinha A, Ewies AA. Non-hormonal topical treatment of vulvovaginal atrophy: an up-to-date overview. *Climacteric* 2013;16:305–12
 29. Berlin AL, Hussain M, Phelps R, Goldberg DJ. A prospective study of fractional scanned nonsequential carbon dioxide laser resurfacing: a clinical and histopathologic evaluation. *Dermatol Surg* 2009;35:222–8
 30. Ong MW, Bashir SJ. Fractional laser resurfacing for acne scars: a review. *Br J Dermatol* 2012;166:1160–9
 31. Tierney EP, Hanke CW. Fractionated carbon dioxide laser treatment of photoaging: prospective study in 45 patients and review of the literature. *Dermatol Surg* 2011;37:1279–90
 32. Tierney EP, Hanke CW. Ablative fractionated CO₂ laser resurfacing for the neck: prospective study and review of the literature. *J Drugs Dermatol* 2009;8:723–31
 33. Peterson JD, Goldman MP. Rejuvenation of the aging chest: a review and our experience. *Dermatol Surg* 2011;37:555–71
 34. Salvatore S, Digesu G, Siesto G, et al. Vaginal collagen remodeling after fractional carbon dioxide laser surgery [abstract 233]. Presented at Annual Meeting of the International Continence Society, Glasgow, United Kingdom, August–September 2011
 35. Ettinger B, Hait H, Reape KZ, Shu H. Measuring symptom relief in studies of vaginal and vulvar atrophy: the most bothersome symptom approach. *Menopause* 2008;15:885–9
 36. Bump RC, Mattiasson A, Bo K, et al. The standardization of terminology of female pelvic organ prolapse and pelvic floor dysfunction. *Am J Obstet Gynecol* 1996;175:10–17
 37. Bachmann GA, Notelovitz M, Kelly SJ, et al. Long-term non-hormonal treatment of vaginal dryness. *Clin Pract Sexuality* 1992;8:3–8
 38. Ware J, Kosinski M, Keller SD. A 12-item Short-Form Health Survey: construction of scales and preliminary tests of reliability and validity. *Med Care* 1996;34:220–33
 39. Christensen K, Doblhammer G, Rau R, Vaupel JW. Ageing populations: The challenges ahead. *Lancet* 2009;374:1196–208
 40. Brincat MP, Baron YM, Galea R. Estrogens and the skin. *Climacteric* 2005;8:110–23
 41. Sartori MG, Feldner PC, Jarmy-Di Bella ZI, et al. Sexual steroids in urogynecology. *Climacteric* 2011;14:5–14
 42. de Villiers TJ, Pines A, Panay N, et al. on behalf of the International Menopause Society. Updated 2013 International Menopause Society recommendations on menopausal hormone therapy and preventive strategies for midlife health. *Climacteric* 2013;16:316–37
 43. Nappi RE, Davis SR. The use of hormone therapy for the maintenance of urogynecological and sexual health post WHI. *Climacteric* 2012;15:267–74
 44. Fournier A, Kernaleguen C, Panjo H, Clavel-Chapelon F, Ringa V. Postmenopausal hormone therapy initiation before and after the Women's Health Initiative in two French cohorts. *Menopause* 2011;18:219–23
 45. Chin SN, Trinkaus M, Simmons C, et al. Prevalence and severity of urogenital symptoms in postmenopausal women receiving endocrine therapy for breast cancer. *Clin Breast Cancer* 2009;9:108–17
 46. Biglia N, Moggio G, Peano E, et al. Effects of surgical and adjuvant therapies for breast cancer on sexuality, cognitive functions, and body weight. *J Sex Med* 2010;7:1891–900
 47. Longo C, Galimberti M, De Pace B, Pellacani G, Bencini PL. Laser skin rejuvenation: epidermal changes and collagen remodeling evaluated by in vivo confocal microscopy. *Lasers Med Sci* 2013;28:769–76
 48. Kohl E, Meierhöfer J, Koller M, et al. Fractional carbon dioxide laser resurfacing of rhytides and photoaging: a prospective study using profilometric analysis. *Br J Dermatol* 2013;170:858–65
 49. Doumouchtsis SK, Chrysanthopoulou EL. Urogenital consequences in ageing women. *Best Pract Res Clin Obstet Gynaecol* 2013;27:699–714